

Functional Electrical Stimulation (FES) for Treatment of Muscle Spasticity and Atrophy in Horses

Sheila J. Schils, MS, Ph.D.

Equine Rehabilitation, EquiNew, LLC, River Falls, Wisconsin, United States sbschils@EquiNew.com

Introduction

Functional electrical stimulation (FES) has been used for over 15 years in equine rehabilitation. Hundreds of case studies show the clinical outcome of the use of FES for equine rehabilitation. FES is the most applicable electrotherapy for equine rehabilitation due to the ability of the device to stimulate deeply into the skeletal support muscles of the horse while obtaining a high compliance.¹ FES is also used for early mobilization after injury or surgery to obtain controlled, precise movement while the horse is confined.² Two case studies have been selected as examples of the applicability of FES to reverse muscle wasting and decrease muscle spasticity in horses.

Aims

Exploring the application and outcomes of the use of FES for rehabilitation in horses may provide useful information for the utilization of FES in human rehabilitation.

Methods

The FES system for horses uses a portable unit weighing about 2 pounds. Electrodes are placed in

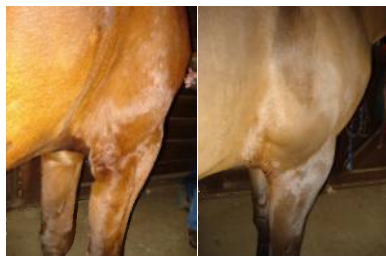


a pad that is administered to the treatment site, or self-stick electrodes can be used. The typical voltage used to produce strong muscle contractions along the top

line is 5-9 volts. Muscle contractions of the triceps typically occurs between 5-7 volts. Treatment time varies from 20 minutes for the triceps and forearm to 35 minutes for top line treatments.

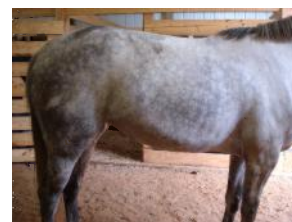Results

The first case study is a horse exhibiting triceps muscle atrophy and uncoordinated fore limb movement. Six FES treatments were performed; 4



treatments to the triceps, 1 treatment to the forearm, and 1 treatment to T10-L3 over a period of 2 months. Voltage ranged from 6.2 on the triceps and forearm, to 9.0 on the top line. Three FES treatments were performed over 2 days spaced 6 weeks apart. The photos show the triceps before treatment and after 6 treatments. The horse was clinically sound after 3 treatments.

The second case study documents the use of FES for severe muscle spasticity of the lumbar/sacral region and the hindquarters. When ridden, the horse persistently reared. Four FES treatments were performed over 2 days; 2 treatments on the sacrum, 1 treatment T13-L6, and 1 treatment on the gluteals. Voltage ranged from 7.4-8.2. After 4 treatments, the mare returned to normal riding activities.



Discussion and Conclusions

Functional electrical stimulation has been utilized to produce encouraging rehabilitation outcomes in horses, however it is not extensively utilized in veterinary medicine. Case studies discussed in this article show examples of the use of FES to reverse muscle atrophy and decrease muscle spasticity. The information obtained from the application of FES to horses may be useful for protocol development in human rehabilitation.

References

1. Schils, S.J. *Review of Electrotherapy Devices for Use in Veterinary Medicine*. Proceedings 55th Annual AAEP Convention, Las Vegas, Dec 5-9, 2009: p. 68-73.
2. Schils, S.J., Turner T.A. *Review of Early Mobilization of Muscle, Tendon, and Ligament After Injury in Equine Rehabilitation*. Proceedings 56th Annual AAEP Convention, Baltimore, Dec 4-8, 2010: p. 374-380.