

EQUINEW FES 310

Clinical Cases

Clinical cases are examples of injuries that have been successfully treated with FES. Specific cases were selected because they were treated exclusively with the FES modality and have documentation of the treatment progress. These examples are offered only as an overview of a specific case, which may or may not apply to another similar case. Each clinical case will provide specific issues unique to that particular horse.

“Joe”

5-year old gelding – Arabian

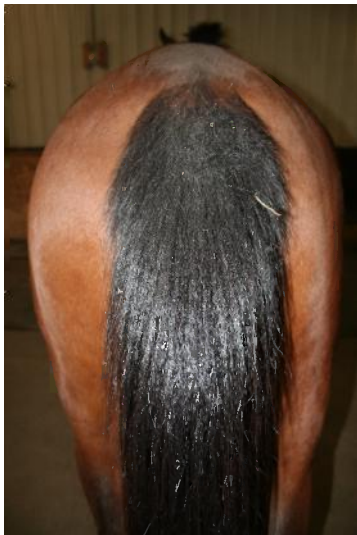Uncoordinated Hind Limb Movement and Hindquarters Muscle Wasting

8 FES Treatments on top line

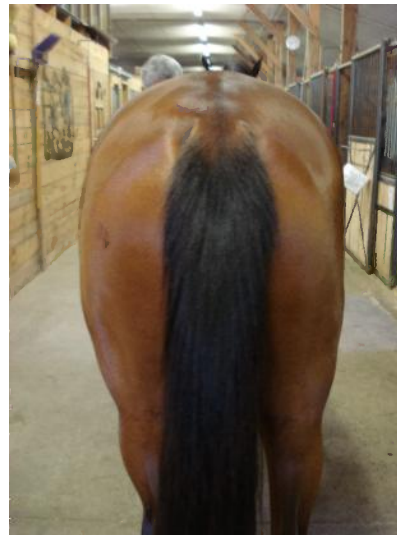3 Movement Evaluations

Until sound at trot and canter during longeing

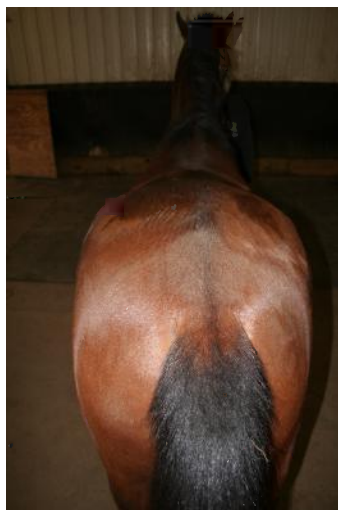
SUMMARY: Upon examination Joe was Grade 3/5 lame in both hind legs. Observation during trotting showed a locked hip positioning the torso to the left while tracking in either direction or straight. Palpation to the lumbar/sacral region produced no rotation and a “drop” in the lumbar area to pressure on the right side of the spine. The right pelvis was low and rolled forward in its position relative to the left. Observation of the dorsal spine showed a “S” shape lateral curve pushing the torso to the left. Left scapula was pushed forward and was higher in position relative to right scapula.



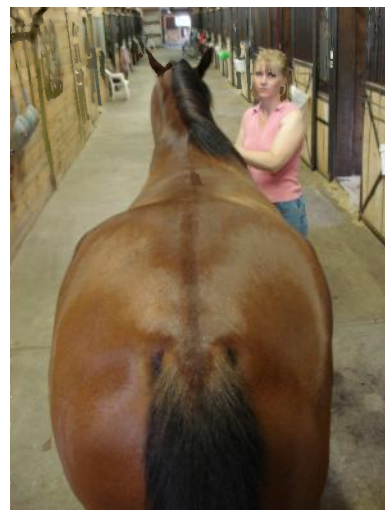4/23 Pre-FES Treatments



6/26 After 7 FES Treatments



4/23 Pre-FES Treatments



6/26 After 7 FES Treatments